

Case Report

Autologous Adipose Tissue-Derived Stem Cells Induce Persistent Bone-Like Tissue in Osteonecrotic Femoral Heads

Jaewoo Pak, MD

From: Miplant Stems Clinic,
Seoul, Korea.

Address correspondence:
J. Pak, MD
Miplant Stems Clinic
32-3 Chungdam-Dong,
Gangnam-Gu, 4th floor
Seoul, Korea.
E-mail:
jaewoopak@gmail.com

Disclaimer: The procedure
described is neither filed
nor registered with the
United States Food and Drug
Administration. Dr. Pak has
financial stake in Miplant
Stems Clinic.
Conflict of interest: None.

Manuscript received:
08/16/2011
Revised manuscript received:
10/08/2011
Accepted for publication:
10/18/2011

Free full manuscript:
www.painphysicianjournal.com

Background: Osteonecrosis, also known as avascular necrosis, of the femoral head is a debilitating disorder that commonly affects 30- to 50-year-old individuals. Currently, definitive treatment is limited to total hip replacement. However, recent studies have demonstrated bone regeneration in the femoral head after the infusion of bone marrow-derived mesenchymal stem cells. In addition, local injection of adipose tissue-derived stem cells has been shown to regenerate medullary bone-like tissue 3 months after treatment. However, there have been no long-term follow-up studies on humans treated with adipose tissue-derived stem cells for osteonecrosis.

Objectives: To determine if treatment with adipose tissue-derived stem cells and platelet-rich plasma leads to the regeneration of medullary bone-like tissue and long-term reduction of hip pain in patients with femoral head osteonecrosis.

Methods: This report of two clinical cases was in compliance with the Declaration of Helsinki. Also, the Korean Food and Drug Administration has allowed the use of adipose tissue-derived stem cells (ADSCs) in medical treatments since 2009. To obtain ADSCs, lipoaspirates were obtained from lower abdominal subcutaneous adipose tissue. The stromal vascular fraction was separated from the lipoaspirates by centrifugation after treatment with collagenase. The stem-cell-containing stromal vascular fraction was mixed with calcium chloride-activated platelet rich plasma and hyaluronic acid, and this mixture was then injected into the diseased hip. The affected hip was reinjected with calcium chloride-activated platelet rich plasma weekly for 4 weeks. Patients were subjected to pre- and post-treatment magnetic resonance imaging (MRI) scans.

Results: Two patients (34- and 39-year-old men) with femoral head osteonecrosis and severe hip pain were treated with adipose-derived stem cells. The MRI scans of the affected hip in both patients showed segmental areas of low signal intensity (T1 axial views) in the subchondral bones with a "double line sign" consistent with osteonecrosis. The visual analog scale score, physical therapy testing, and Harris Hip score of both patients improved after stem cell treatment. Both patients also demonstrated post-procedure improvement in their MRI scans, evidenced by positive T1 signal changes consistent with medullary bone regeneration. Further, the long-term reduction in hip pain was correlated with the MRI findings indicative of bone regeneration.

Limitations: A biopsy of the regenerated tissue was not conducted in either patient. Thus, the true nature of the treatment-induced changes is unknown. Further, the MRI results may contain artifacts due to the difficulty in capturing the exact treatment location. It can only be speculated that there was neovascularization to support the newly regenerated medullary bone-like tissue.

Conclusion: These 2 cases demonstrate the presence of sustained, regenerated medullary bone-like tissue in 2 severely necrotic femoral heads and suggest that this rather simple, minimally invasive percutaneous procedure may hold great promise as a therapy for patients with femoral head osteonecrosis.

Key words: Femoral head osteonecrosis, avascular necrosis, bone necrosis, cell-based treatment, bone regeneration, hip pain, adipose tissue-derived stem cells, ADSC.

Pain Physician 2012; 15:75-85

Osteonecrosis, also known as avascular necrosis, of the femoral head is a painful disorder that commonly affects 30- to 50-year-old individuals. In the United States, it is estimated that 15,000-20,000 new cases of femoral head osteonecrosis occur each year (1). As necrosis progresses, the femoral head may collapse, which can cause symptomatic arthritis and necessitate total hip replacement (THR). In North America, osteonecrosis is the reason for approximately 5-8% of the more than 500,000 total hip arthroplasties performed annually (1).

In osteonecrosis, the osteocytes in the cortical bones and the bone marrow are destroyed due to insufficient blood circulation. As a pathological entity, osteonecrosis is defined by empty lacunae in the osseous matrix and necrotic bone marrow in the interstices of the trabeculae (2). The region of necrosis is surrounded by reparative tissues, including neovasculature and newly formed bone (2,3). Unfortunately, this healing process does not return the femoral head's structural stability to its predisease state (4,5).

The exact mechanism causing decreased blood circulation to the femoral head is currently unknown. However, trauma, alcohol, and steroid use are highly correlated with this disease and are considered possible causes. Current research led to the development of a number of theories for the mechanism of this disease, including venous occlusion, vessel wall injury, fat embolism, microfracture from trabecular insufficiency, intraosseous hypertension, intraosseous hemorrhage, vasculitis, and intravascular coagulation (6-12).

THR remains the only definitive treatment for femoral head osteonecrosis, but has drawbacks. Although necrotic tissue is completely removed prior to reconstruction with an implant, the durability and longevity of the artificial implants (implants typically fail after approximately 15 years) are not satisfactory in younger patients because the procedure may need to be repeated 2 to 3 times in a patient's lifetime (13, 14). Moreover, THR requires a prolonged period of postoperative recovery and physical therapy.

In June 2009, due to increasing use of adipose tissue and adipose tissue-derived stem cells (ADSCs) by plastic surgeons, the Korean Food and Drug Administration officially allowed the use of ADSCs in autologous cell transplantation as long as they were obtained and processed within the same medical facility with minimal processing (15,16). Thus, adipose tissue can now be used as a source of mesenchymal stem cells (MSCs) in Korea.

MSCs are found in numerous human tissues, including bone marrow and adipose tissue. These cells have been shown to differentiate into various connective tissues, including bones and blood vessels (17-27). Lipoaspirates from liposuctioned adipose tissue contain many different types of cells, including stem cells, pericytes, fibroblasts, endothelial cells, and pre-adipocytes. Among these cells, stem cells and pericytes have received significant attention. The pericytes in the stromal vascular fraction of adipose tissue express surface markers similar to those expressed on stem cells in the bone marrow (28). These pericytes have been shown to differentiate into blood vessels, and there is speculation that pericytes and stem cells are identical entities (28).

In 2002, Hernigou and Beaujean (29) reported that autologous bone marrow transfer led to positive results in 145 cases of femoral head osteonecrosis. In 2004, Gangji et al (30) published a double-blind, prospective study of 18 cases of femoral head osteonecrosis treated with concentrated bone marrow aspirates that showed positive results. Gangji et al (31) again reported positive results in 2005 in a large trial in which autologous mononuclear bone marrow cells were implanted into the femoral head. This report demonstrated a significant reduction in further osteonecrosis-caused deterioration, and was supported by subsequent imaging studies. In 2008, Centeno et al (32) reported regeneration of human hip bones with autologous culture-expanded bone marrow-derived stem cells. In 2009, Wang et al (33) reported positive results (including an 80% success rate) in a study of 59 patients with femoral head osteonecrosis treated with concentrated bone marrow. Pak (34) reported the short-term regeneration of medullary bone-like tissue in osteonecrotic femoral heads in humans treated with ADSCs in 2011. The likelihood of bone regeneration adds to accumulating evidence that MSCs may play a major role in regenerating bone-like tissue in femoral head osteonecrosis.

Platelet rich plasma (PRP) has been mixed with ADSCs to provide the necessary growth factors and differentiating factors. PRP contains multiple growth factors, including transforming growth factor, insulin-like growth factor, fibroblast growth factor, and platelet-derived growth factor. PRP has been shown to have positive effects on the stimulation of bones, blood vessels, and the formation of chondrocytes (35-38). Further, hyaluronic acid has been added to ADSCs to act as a scaffolding material, and calcium chloride has been used as a PRP-activating agent (39).

We are not aware of any published reports on the long-term persistence of regenerated medullary bone-like tissue in the osteonecrotic femoral heads of patients treated with ADSCs. Although the cases mentioned above add to the growing evidence that MSCs may be useful for bone regeneration, more research with a larger number of patients is needed to determine whether this technique has clinical merit. However, this simple percutaneous procedure to repair a necrotic femoral head may represent a promising, minimally invasive, nonsurgical alternative for prolonged pain reduction and the delaying of THR.

Patient Characteristics

This case study demonstrates long-term reduction of hip pain in patients with femoral head osteonecrosis treated with ADSCs and PRP, presumably through regeneration of bone.

Patient #1

The first patient is a 39-year-old Korean man with right hip pain due to osteonecrosis of the femoral head (stage 4, as diagnosed by an orthopedic surgeon) who was offered THR. The patient tried oral nonsteroidal anti-inflammatory drugs (NSAIDs) along with acetaminophen for his pain, but this combination did not provide relief. On admission, the Harris Hip Score was as follows: pain subscale = 10, function subscale = 14, deformity subscale = 0, motion subscale = 3, total score = 27 out of 100. The visual analog score (VAS) was 7 at rest and 9 when standing and

walking. The functional rating index (40) and range of motion (ROM) on physical therapy were decreased (Table 1). Magnetic resonance imaging (MRI) T1 axial views of the affected hip showed low signal intensity in the femoral head and a classic segmental area of osteonecrosis with a dark line denoting the border between dead and live bone.

Patient #2

The second patient is a 34-year-old Korean man with right hip pain due to osteonecrosis of the femoral head (stage 3). Although this patient was only diagnosed with stage 3 osteonecrosis by an orthopedic surgeon, he was offered THR due to severe pain not alleviated by the oral intake of NSAIDs and tramadol. On admission, the Harris hip score was as follows: pain subscale = 10, function subscale = 36, deformity subscale = 0, motion subscale = 4, total score = 50 out of 100. The VAS score was 6 at rest and 8 when standing and walking, and the functional rating index and ROM were moderately decreased (Table 2). MRI T1 axial views of the affected hip showed low signal intensity and the classic signs of osteonecrosis.

METHODS

This series of clinical cases was in compliance with the Declaration of Helsinki. Also, the Korean Food and Drug Administration has allowed the use of ADSCs in medical treatments since 2009. Informed consent was obtained from each patient. The inclusion criteria, exclusion criteria, and outcome are listed in Tables 3-5.

Table 1. Patient 1 functional rating index, visual analog score (VAS), and Harris hip score.

Outcome Measures	Pre-injection	3 Months Post-injection	6 Months Post-injection	12 Months Post-injection
Functional Rating Index	15	8	7	7
VAS Walking Index	9	3	2	2
Harris Hip Score	27	71	71	71

Physical therapy, range of motion.

PT Session	Flexion (degrees)	Flexion VAS	Abduction (degrees)	Abduction VAS	Adduction (degrees)	Adduction VAS
Pre-injection Evaluation	100	9	20	8	15	9
3 Months Post-injection	120	2	30	2	20	2
6 Months Post-injection	120	1	30	2	20	1
12 Months Post- injection	120	1	30	2	20	1

Table 2. Patient 2 functional rating index, visual analog score (VAS), and Harris hip score

Outcome Measures	Pre-injection	3 Months post-injection	6 months Post-injection	12 months Post-injection
Functional Rating Index	15	8	7	7
VAS Walking Index	8	2	2	2
Harris Hip Score	50	96	96	96

Physical therapy, range of motion

PT Session	Flexion (degrees)	Flexion VAS	Abduction (degrees)	Abduction VAS	Adduction (degrees)	Adduction VAS
Pre-injection Evaluation	110	8	30	6	20	9
3 Months Post-injection	125	1	40	1	25	2
6 Months Post-injection	125	1	40	1	25	1
12 Months Post- injection	125	1	40	1	25	1

Table 3. Inclusion criteria

1. MRI evidence of osteonecrosis
2. Orthopedic evaluation that determined that patient was a candidate for a unipolar or bipolar hip prosthesis
3. Either male or female
4. Under 60 years of age
5. An unwillingness to proceed with hip prosthesis
6. The failure of conservative management
7. Ongoing disabling pain

Table 4. Exclusion criteria

1. Active inflammatory or connective tissue disease thought to affect the patient's pain (i.e., lupus, rheumatoid arthritis, fibromyalgia)
2. Active endocrine disorder that might affect the patient's pain (i.e., hypothyroidism, diabetes)
3. Active neurological disorder that might affect the patient's pain (i.e., peripheral neuropathy, multiple sclerosis)
4. Active cardiac disease
5. Active pulmonary disease requiring the use of medication

Table 5. Outcome endpoints (obtained at 3, 6, and 12 months post-treatment)

1. Pre- and post-treatment VAS
2. Pre- and post-treatment Functional Rating Index
3. Pre- and post-treatment Range of Motion
4. Pre- and post-treatment MRI

Medication Restrictions

Patients were restricted from taking steroids, aspirin, NSAIDs, and Asian herbal medications for one week prior to the procedure.

Liposuction

In the operating room, approximately 40 g of packed adipose tissue were obtained by liposuction of the subcutaneous layer of the lower abdominal area using sterile techniques (34).

ADSC treatment

ADSCs were extracted through the use of digestive enzymes (0.07% type 1 collagenase) and centrifugation (41). The total volume of the solution containing the stem cells was approximately 8 mL. While preparing the ADSCs, 30 mL autologous blood were drawn along with 2.5 mL anticoagulant citrate dextrose solution. After centrifugation, approximately 4 mL of platelet-rich plasma along with the Buffy coat were obtained. Hyaluronic acid (one mL) was added as a scaffold to this mixture, and CaCl₂ was added to activate PRP.

After the right hip was cleaned with povidone-iodine and draped in a sterile fashion, the injection site was anesthetized with 2% lidocaine. The stem cell mixture was injected into the femoral head posterolaterally with a 22-gauge, 3 1/2-inch needle under ultrasonic guidance. The patient returned to the clinic for CaCl₂-activated PRP injections every week for 4 weeks.

RESULTS

It has been estimated that approximately 400,000 ADSCs are contained in one g of adipose tissue (42). Since 40 grams of centrifuged adipose tissue were harvested, it is believed that approximately 16,000,000 stem cells were extracted and injected into the diseased hip. After 2 weeks of ADSC-PRP mixture injections, both patients noticed a reduction in hip pain.

The hip pain continued to improve up to the 12th week post-treatment. The VAS pain scores, functional rating indices, ROM testing scores, and Harris Hip Scores of both patients were all dramatically improved (Patient 1, Table 1; Patient 2, Table 2). Further, the post-procedure MRIs of both patients showed changes consistent with bone regeneration (Figs. 1-6).

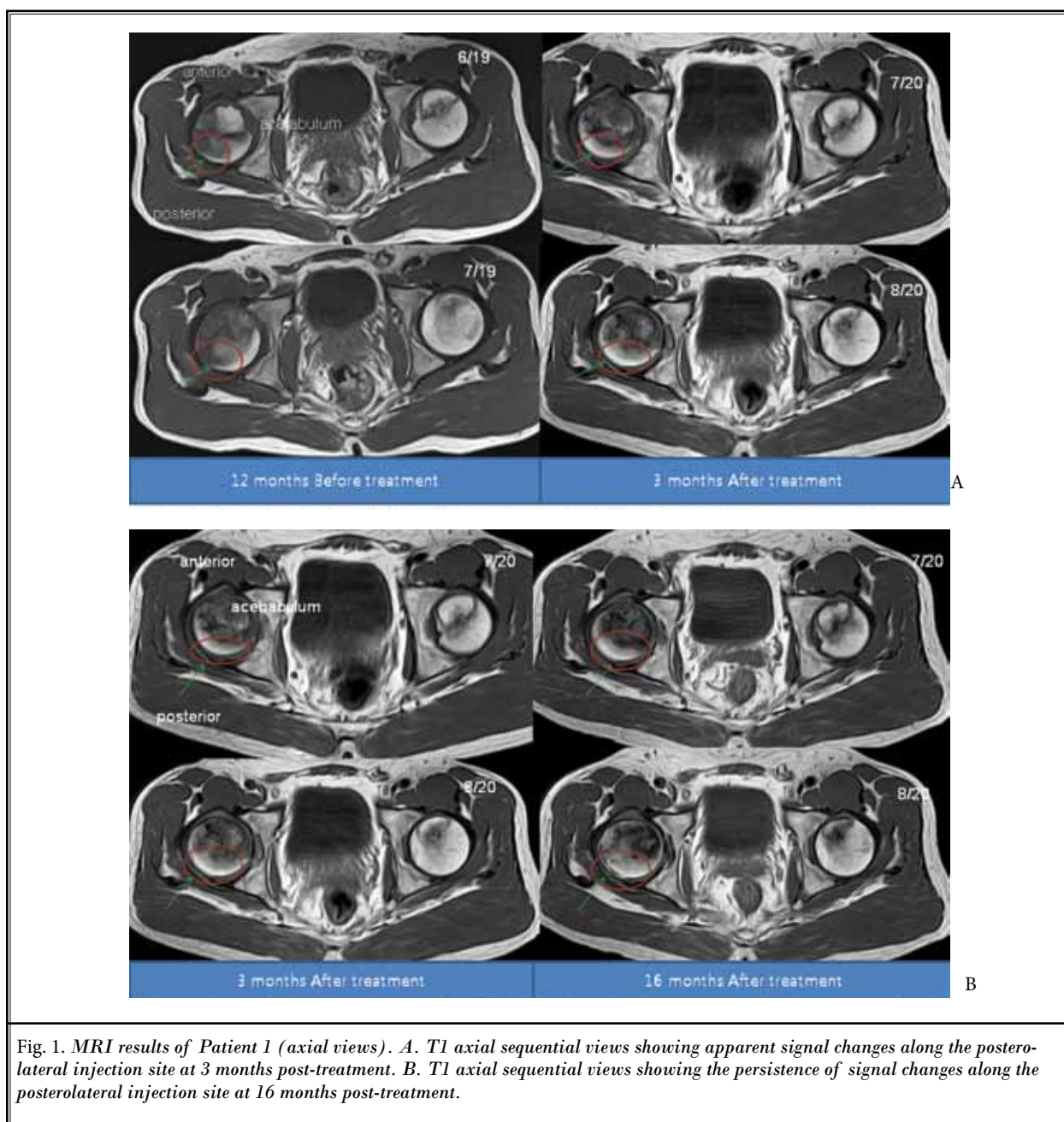
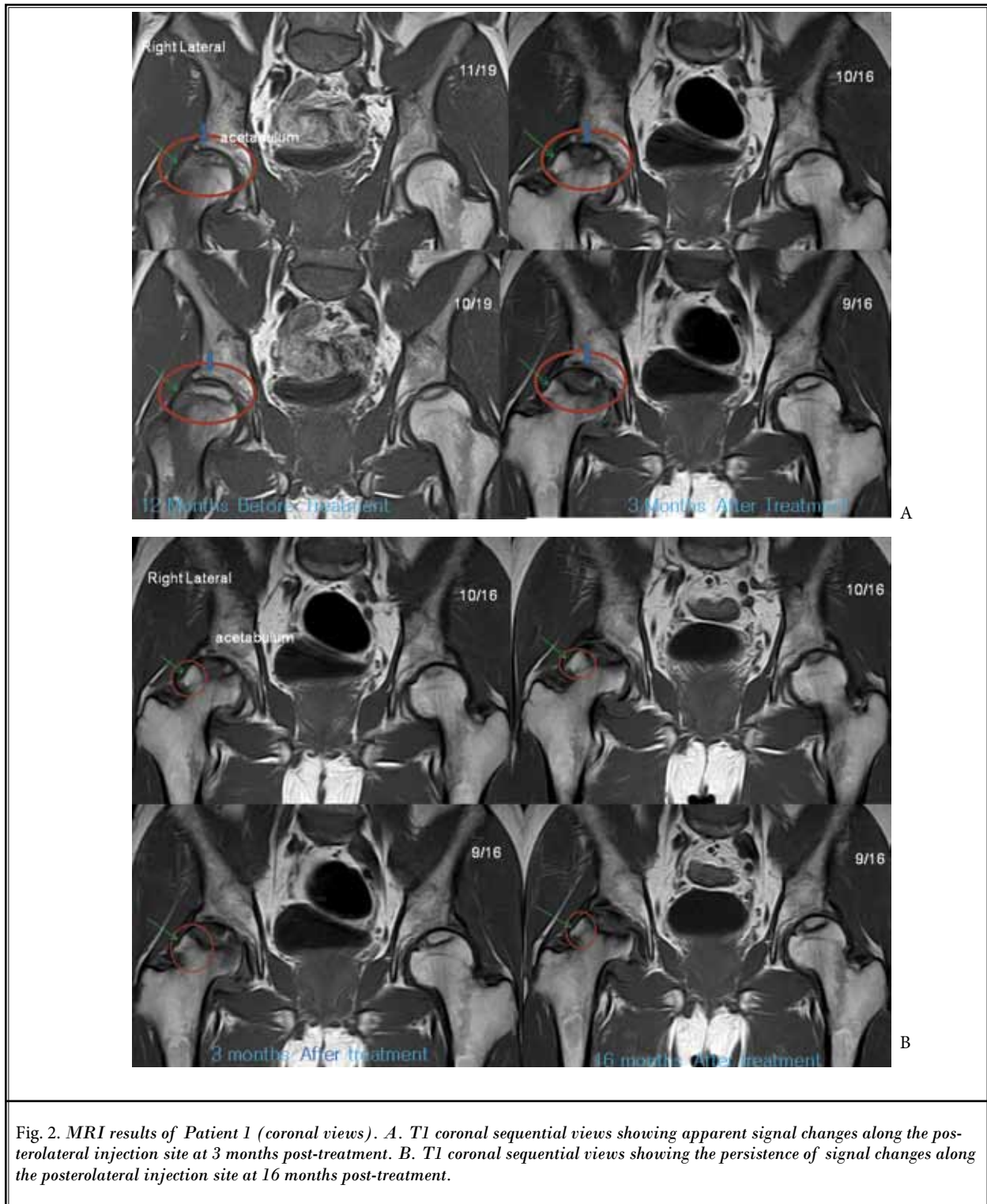
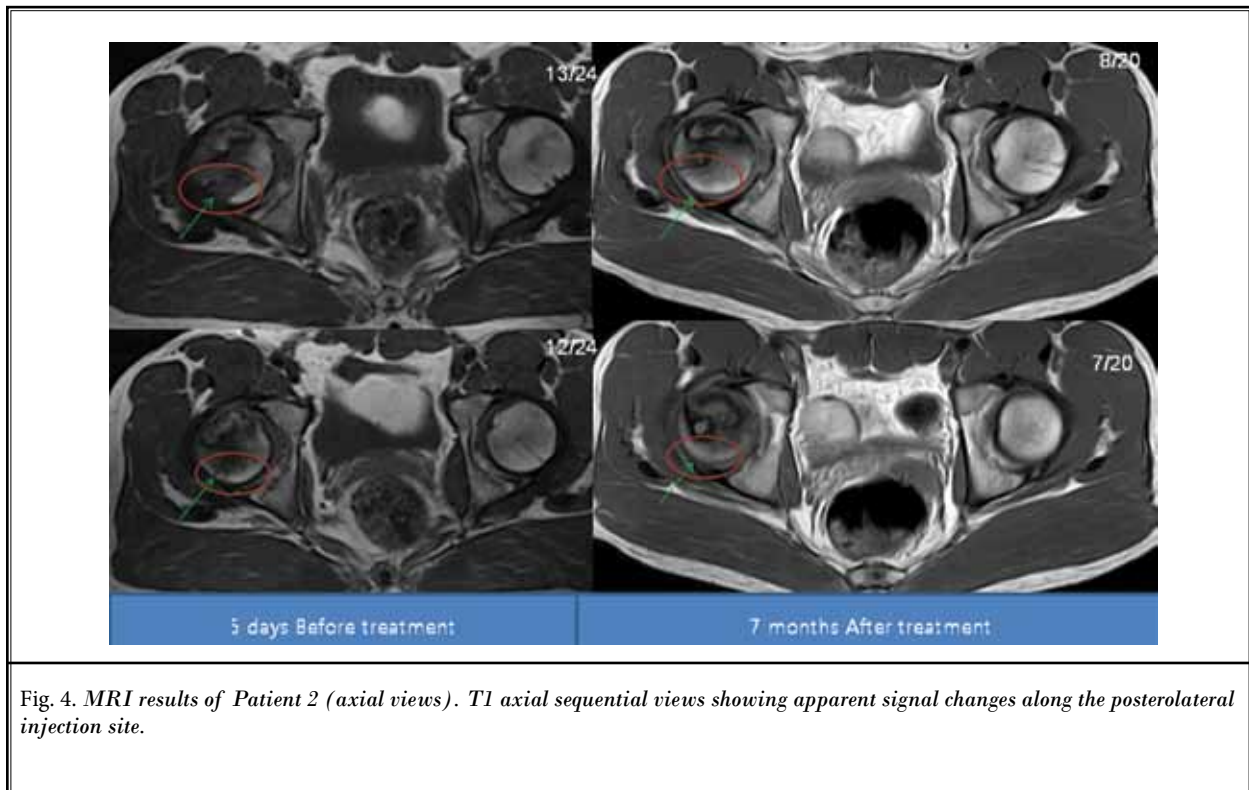
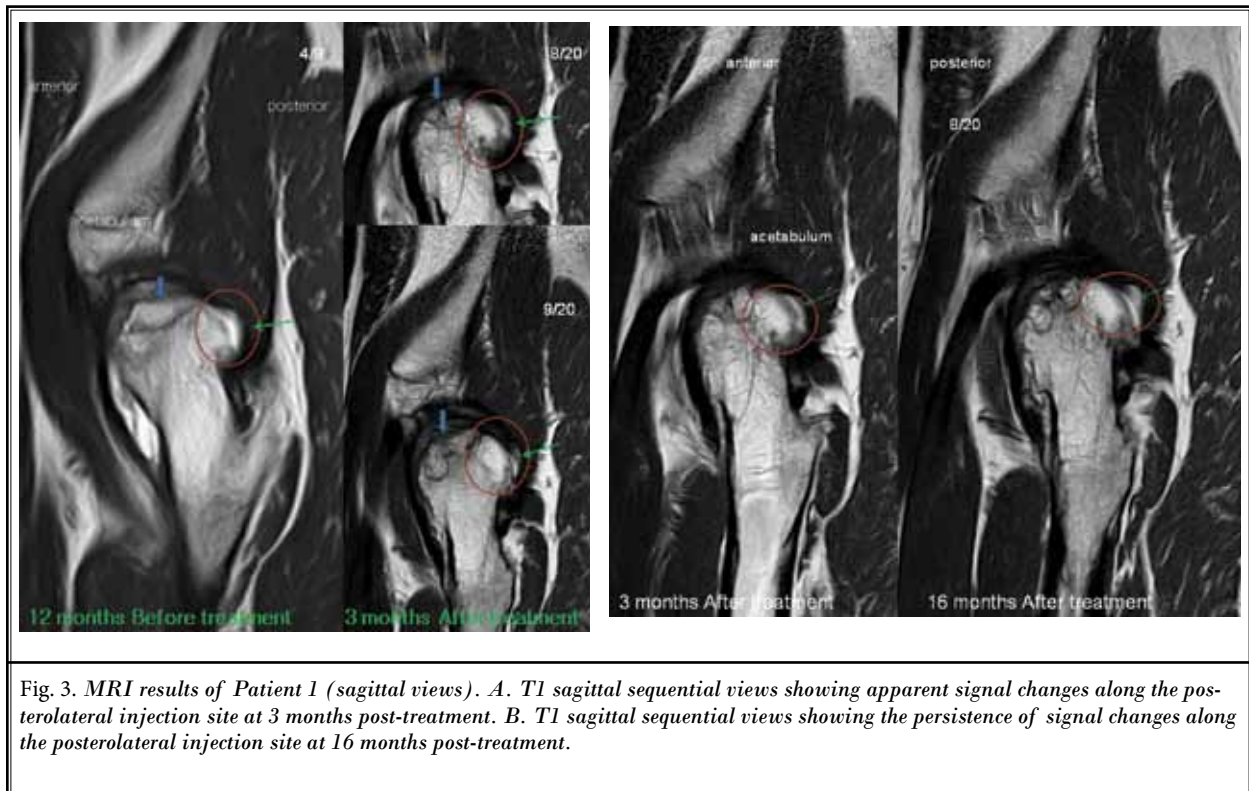


Fig. 1. MRI results of Patient 1 (axial views). A. T1 axial sequential views showing apparent signal changes along the posterolateral injection site at 3 months post-treatment. B. T1 axial sequential views showing the persistence of signal changes along the posterolateral injection site at 16 months post-treatment.





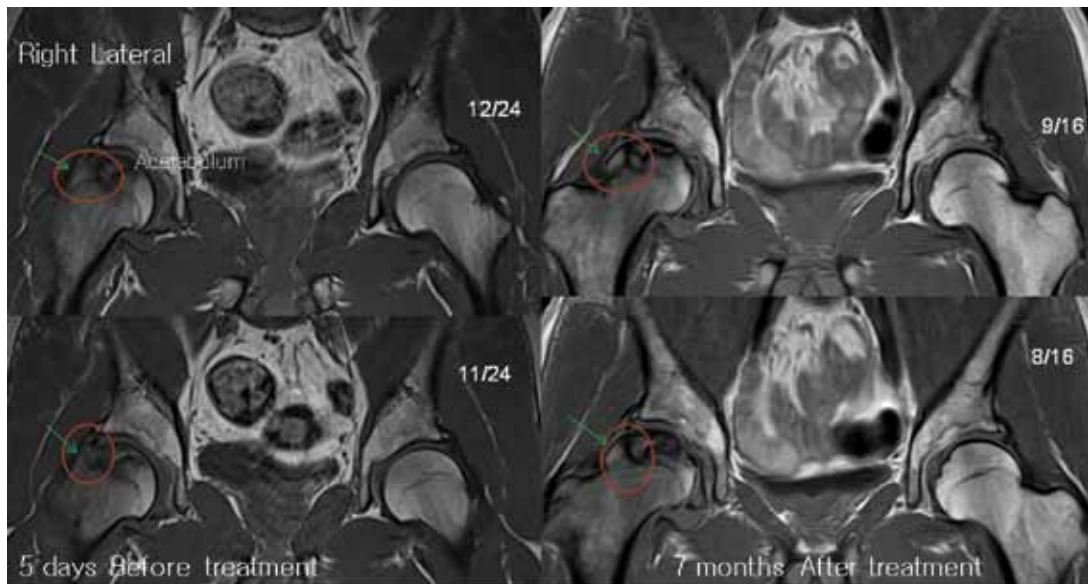


Fig. 5. MRI results of Patient 2 (coronal views). T1 coronal sequential views showing apparent signal changes along the posterolateral injection site.

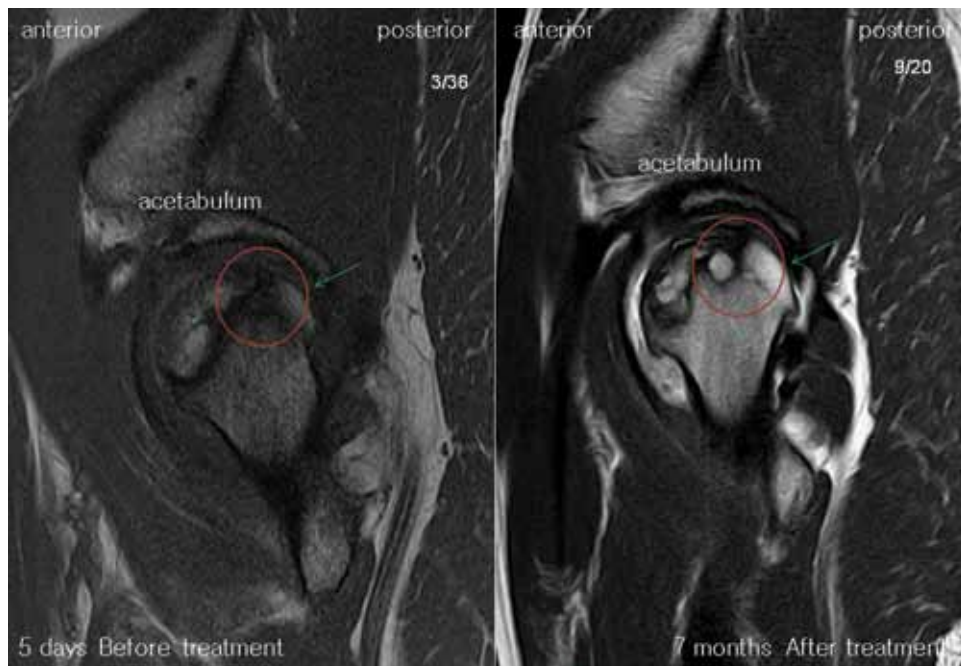

Fig. 6. MRI results of Patient 2 (sagittal views). T1 sagittal views showing apparent signal changes along the posterolateral injection site.

DISCUSSION

An MRI of the hip was performed on both patients before ADSC treatment for diagnosis. Consequently, post-ADSC treatment MRIs were performed to compare pre- and post-treatment images. The MRI T1 sequence was used for its ability to show bony anatomy. Due to slight differences in patient positioning and slight movement of patients during the MRI procedures, there was some difficulty in capturing the exact treatment location. However, the pre-and post-MRI results can be compared with sequential views to compensate for any possible errors. Further, the slight differences in signal changes between pre- and post-treatment MRIs can be compensated for by comparing the newly-regenerated tissue with the surrounding acetabulum.

In this case series, significant MRI signal changes were apparent in the T1 views of the femoral head along the posterolateral injection site. These significant signal changes can be interpreted as probable signs of persistent, regenerated medullary bone. For Patient 1, the medullary bone regeneration was sustained for at least 16 months, and for at least 7 months in Patient 2. Due to reduction in hip pain, both patients were reluctant to undergo a hip bone biopsy to determine the true nature of the bone-like tissue. Without the biopsy, the true nature of the newly-formed tissue could not be determined. However, based on the comparison of this tissue to the surrounding acetabulum, the tissue is believed to be hydroxyapatite in nature, and the dramatic reduction in hip pain supports this notion.

With regard to the possibility of new blood vessel formation, it is speculated that there must have been concomitant neovascularization to support the newly-regenerated medullary bone-like tissue because without neovascularization, the newly-regenerated tissue could not have survived for a prolonged period. Thus, the presence/absence of neovascularization should be investigated by contrast medium-enhanced MRI in a future study.

Another advantage of this simple, minimally invasive procedure is the reduction in adipose tissue. Being overweight can be detrimental for a patient with femoral head osteonecrosis. In this procedure, the patient may lose a few hundred grams of unwanted adipose tissue through liposuction, which may be of some benefit.

CONCLUSION

These 2 cases demonstrate the presence of sustained, regenerated medullary bone-like tissue in 2 severely necrotic femoral heads. The newly regenerated tissue was sustained for more than 16 months in one patient and 7 months in the other. In both patients, the reduction in pain persisted after the post-procedure MRIs. This is the first report that describes a relatively long-term reduction in pain thought to be due to the regeneration of medullary bone-like tissue. When considered in conjunction with previous studies that involved bone marrow-derived stem cells, these 2 cases suggest that it is likely that ADSCs help lead to the regeneration of bone when administered to an osteonecrotic femoral head.

We are unaware of any published reports on the induction of long-term persistent regenerated medullary bone-like tissue in humans treated with ADSCs for femoral head osteonecrosis. More research with a greater number of patients is needed to determine if this technique has clinical merit. This simple, minimally invasive percutaneous procedure may hold great promise as a therapy for patients with femoral head osteonecrosis..

DISCLAIMER

This report of 2 cases was not funded by any external funding source. The procedure described is neither filed nor registered with the United States Food and Drug Administration.

Consent

Written informed consent was obtained from all patients for publication of this case report and all accompanying images. Copies of the written consent forms are available for review by the Editor-in-Chief of this journal.

Competing interests

None declared.

Authors' contributions

JP was in charge of patient treatment and follow-up and manuscript drafting and revision, and read and approved the final manuscript.

Acknowledgements

JP acknowledges the support from the staff of Mi-plant Stems Clinic and Dr. Taehaeng Huh of the Seoul Radiology Group.

REFERENCES

1. Jones K, Seshadri T, Krantz R, Keating A, Ferguson P. Cell-based therapies for osteonecrosis of the femoral head. *Biol Blood Marrow Transplant* 2008; 14:1081-1087.
2. Glimcher MJ, Kenzora JE. The biology of osteonecrosis of the human femoral head and its clinical implications: II. The pathological changes in the femoral head as an organ and in the hip joint. *Clin Orthop Relat Res* 1979; 139:283-312.
3. Inoue A, Ono K. A histological study of idiopathic avascular necrosis of the head of the femur. *J Bone Joint Surg Br* 1979; 61-B:138-143.
4. Springfield DS, Enneking WJ. Surgery for aseptic necrosis of the femoral head. *Clin Orthop Relat Res* 1978; 103:175-185.
5. Mont MA, Carbone JJ, Fairbank AC. Core decompression versus nonoperative management for osteonecrosis of the hip. *Clin Orthop Relat Res* 1996; 324:169-178.
6. Chandler FA. Coronary disease of the hip. 1949. *Clin Orthop Relat Res* 2001; 386:7-10.
7. Saito S, Ohzono K, Ono K. Early arteriopathy and postulated pathogenesis of osteonecrosis of the femoral head. The intracapsular arterioles. *Clin Orthop Relat Res* 2001; 277:98-110.
8. Jones JP Jr. Fat embolism and osteonecrosis. *Orthop Clin North Am* 1985; 16:595-633.
9. Hungerford DS, Lennox DW. The importance of increased intraosseous pressure in the development of osteonecrosis of the femoral head: Implications for treatment. *Orthop Clin North Am* 1985; 16:635-654.
10. Saito S, Inoue A, Ono K. Intramedullary haemorrhage as a possible cause of avascular necrosis of the femoral head. The histology of 16 femoral heads at the silent stage. *J Bone Joint Surg Br* 1987; 69:346-351.
11. Wang TY, Avlonitis EG, Relkin R. Systemic necrotizing vasculitis causing bone necrosis. *Am J Med* 1988; 84:1085-1086.
12. Jones JP Jr. Fat embolism, intravascular coagulation, and osteonecrosis. *Clin Orthop Relat Res* 1993; 292:294-308.
13. Garino JP, Steinberg ME. Total hip arthroplasty in patients with avascular necrosis of the femoral head: A 2- to 10-year follow-up. *Clin Orthop Relat Res* 1997; 334:108-115.
14. Katz RL, Bourne RB, Rorabeck CH, McGee H. Total hip arthroplasty in patients with avascular necrosis of the hip. Follow-up observations on cementless and cemented operations. *Clin Orthop Relat Res* 1992; 281:145-151.
15. Billing E, May JW. Historical review and present status of free fat graft autotransplantation in plastic and reconstructive surgery. *Plast Reconstr Surg* 1989; 83:368-381.
16. Korean Food and Drug Administration. Cell therapy. In *Korean Food and Drug Administration Rules and Regulations*. Seoul, Korea: Food and Drug Administration; Chapter 2, Section 12.
17. Barry FP. Mesenchymal stem cell therapy in joint disease. *Novartis Found Symp* 2003; 249:86-96, discussion 96-102, 170-174, 239-241.
18. Gimble J. Adipose tissue-derived therapeutics. *Expert Opin Biol Ther* 2003; 3:705-713.
19. Caplan AI. Mesenchymal stem cell. *J Orthop Res* 1991; 9:641-650.
20. Carter DR, Beaupré GS, Giori NJ, Helms JA. Mechanobiology of skeletal regeneration. *Clin Orthop Relat Res* 1998; (355 Suppl):S41-55.
21. Johnstone B, JU Yoo. Autologous mesenchymal progenitor cells in articular cartilage repair. *Clin Orthop Relat Res* 1999; (367 Suppl):S156-162.
22. Luyten FP. Mesenchymal stem cells in osteoarthritis. *Curr Opin Rheumatol* 2004; 16:599-603.
23. Magne D, Vinatier C, Julien M, Weiss P, Guicheux J. Mesenchymal stem cell therapy to rebuild cartilage. *Trends Mol Med* 2005; 11:519-526. Epub 2005 Oct 5.
24. Murphy JM, Fink DJ, Hunziker EB, Barry FP. Stem cell therapy in a caprine model of osteoarthritis. *Arthritis Rheum* 2003; 48:3464-3474.
25. Nevo Z, Robinson D, Horowitz S, Hasharoni A, Yayon A. The manipulated mesenchymal stem cells in regenerated skeletal tissues. *Cell Transplant* 1998; 7:63-70.
26. Noel D, Djouad F, Jorgense C. Regenerative medicine through mesenchymal stem cells for bone and cartilage repair. *Curr Opin Investig Drugs* 2002; 3:1000-1004.
27. Schaffler A, Buchler A. Concise Review: Adipose tissue-derived stromal cells—basic and clinical implications for novel cell-based therapies. *Stem Cells* 2007; 25:818-827.
28. Traktuev DO, Merfeld-Claus S, Li J, Kolonin M, Arap W, Pasqualini R, Johnstone BH, March KL. A population of multipotent CD34-positive adipose stromal cells share pericyte and mesenchymal surface markers, reside in a periendothelial location, and stabilize endothelial networks. *Circ Res* 2008; 102:77-85.
29. Hernigou P, Beaujean F. Treatment of osteonecrosis with autologous bone marrow grafting. *Clin Orthop Relat Res* 2002; 405:14-23.
30. Gangji V, Hauzeur JP, Matos C, De Maertelaer V, Toungouz M, Lambermont M. Treatment of osteonecrosis of the femoral head with implantation of autologous bone-marrow cells: A pilot study. *J Bone Joint Surg Am* 2004; 86:1153-1160.
31. Gangji V, Toungouz M, Hauzeur JP. Stem cell therapy for osteonecrosis of the femoral head. *Expert Opin Biol Ther* 2005; 5:437-442.
32. Centeno CJ, Buse D, Kisdajy J, Keohan C, Freeman M, Karli D. Increased knee cartilage volume in degenerative joint disease using percutaneously implanted, autologous mesenchymal stem cells. *Pain Physician* 2008; 11:343-353.
33. Wang BL, Sun W, Shi ZC, Zhang NF, Yue DB, Guo WS, Xu SQ, Lou JN, Li ZR. Treatment of nontraumatic osteonecrosis of the femoral head with the implantation of core decompression and concentrated autologous bone marrow containing mononuclear cells. *Arch Orthop Trauma Surg* 2009; 130:1-7.
34. Pak J. Regeneration of human bones in hip osteonecrosis and human cartilage in knee osteoarthritis with adipose-tissue-derived stem cells. *J Med Case Reports* 2011; 5:296.
35. Parsons P, Hesselden K, Butcher A, Maughan J, Milner R, Horner A. The biological effect of platelet rich-plasma on the fracture healing process. *J Bone Joint Surg Br* 2009; 91B(Suppl 2):293-c.
36. Li N, Yuan R, Chen T, Chen L, Jin X. Effect of platelet-rich plasma and latissimus dorsi muscle flap on osteogenesis and vascularization of tissue-engineered bone in dog. *J Oral Maxillofac Surg* 2009; 67:1850-1858.
37. Wu W, Chen F, Liu Y, Ma Q, Mao T. Autologous injectable tissue-engineered cartilage by using platelet-rich plasma: Experimental study in a rabbit model. *J Oral Maxillofac Surg* 2007; 65:1951-1957.
38. Caplan A, Correa D. PDGF for bone formation and regeneration: New insights into a novel mechanism involving MSCs. *J Orthop Res* 2011; 29:1795-1803.
39. Martineau I, Lacoste E, Gagnon G. Effects of calcium and thrombin on

- growth factor release from platelet concentrates: Kinetics and regulation of endothelial cell proliferation. *Biomaterials* 2004, 25:4489-4502.
40. Childs JD, Piva SR. Psychometric properties of the functional rating index in patients with low back pain. *Eur Spine J* 2005; 14:1008-12.
41. Zuk PA, Zhu M, Ashjian P, De Ugarte DA, Huang JJ, Mizuno H, Alfonso ZC, Fraser JK, Benhaim P, Hedrick MH. Human adipose tissue is a source of multipotent stem cells. *Mol Biol Cell* 2002; 13:4279-4295.
42. Aust L, Devlin B, Foster SJ, Halvorsen YD, Hicok K, du Laney T, Sen A, Willingmyre GD, Gimble JM. Yield of human adipose-derived adult stem cells from liposuction aspirates. *Cytotherapy* 2004; 7-14.

